



## Case Report

# Anterior Ectopic Anus in Scrotum with Subcoronal Hypospadias in a Neonate: A Case Report

Prashant Patil<sup>1</sup>, Abhay Gupta<sup>1</sup>, Shahaji Deshmukh<sup>1</sup>, Prasad Bansod<sup>2,\*</sup>

<sup>1</sup>Dept of Paediatric surgery, L. T. M. G. Hospital, Sion, Mumbai, Maharashtra, India

<sup>2</sup>Dept. of Surgery, NKP Salve Institute of Medical Sciences, Nagpur, Maharashtra, India

### Email address:

Rabbu7288@gmail.com (P. Bansod)

\*Corresponding author

### To cite this article:

Prashant Patil, Abhay Gupta, Shahaji Deshmukh, Prasad Bansod. Anterior Ectopic Anus in Scrotum with Subcoronal Hypospadias in a Neonate: A Case Report. *International Journal of Biomedical Engineering and Clinical Science*. Vol. 3, No. 6, 2017, pp. 81-84.

doi: 10.11648/j.ijbecs.20170306.12

Received: September 30, 2016; Accepted: January 14, 2017; Published: November 10, 2017

**Abstract:** Ectopic anus is an atypical uncommon variant of broad spectrum of anorectal malformation. We present a case of a 22 day old neonate with anus placed within scrotum. After surgical intervention a neoanus was created within sphincter complex and good functional result was achieved. Patient had urethral injury intraoperatively which was managed by urethrostomy. Subcoronal hypospadias and urethrostomy was corrected in second setting.

**Keywords:** Anal Position, Anterior Displacement of Anus, Infant Recto Perineal Fistula, Ectopic Anus, Anorectal Malformation, Anoplasty, Sphincter Complex

## 1. Introduction

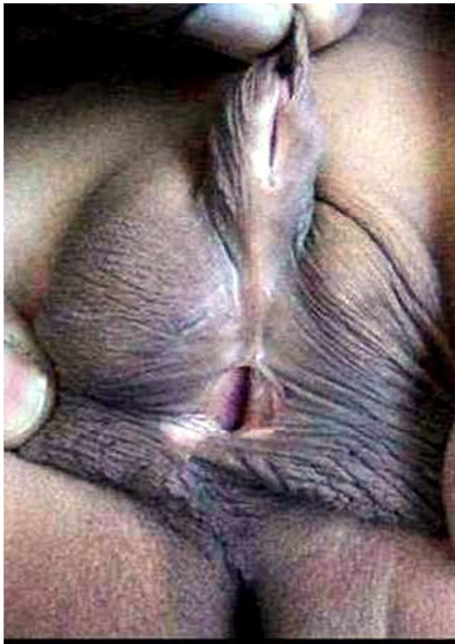Anterior ectopic anus is a common congenital abnormality that is commonly missed, underreported and very little is written about. Anterior displacement of the anus (ADA), a common congenital abnormality of anorectal region, has been recognized as a common cause of constipation. It has been estimated that more than one third of children examined for chronic constipation have an anterior ectopic anus. ADA is a common variant of the normal anatomical location of the anus, especially in girls. Mild forms of imperforate anus are often called anal stenosis or anterior ectopic anus. [1, 2]. The normal anal position is midway between the vaginal fourchette and coccyx in females and the scrotum and coccyx in males. In order to define the normal position of anus, there is a quantitative measurement using the anal position index (API), the ratio of anal-fourchette distance to coccyx-fourchette distance for females and the ratio of anal-scrotum distance to coccyx-scrotum distance for males. API less than 0.46 in boys and less than 0.34 in girls is indicative of anterior displacement of anus. Anterior ectopic anus is diagnosed if the anal position index is less than 0.46 in

boys and less than 0.34 in girls [5]. Mean API values in late preterm infants, with subsequent analysis demonstrating that API values differ between preterm and term neonates. API also has utility in preventing complications associated with incorrect anal placement, such as fecal incontinence and constipation [6] There are several operative procedures to treat anterior ectopic anus and some of these procedures are extensive and may necessitate a preliminary colostomy [2, 8, and 9]. This report presents our experience with anterior ectopic anus and describes a modified surgical technique.

## 2. Case Report

A full term male child, 2.8 kg, delivered vaginally was referred on day of life 22 for complaint of passage of meconium through anus placed within scrotum. (Fig. 1) Baby had passed urine from subcoronal meatus. Clinical examination revealed active child, stable vital parameters. Per abdomen examination was normal. Perineal examination showed dimple with midline raphe at the actual site of anus, well developed and symmetric gluteal folds. Skin lined anal opening seen within bifid scrotum admitting No.24 anal

dilator. Both testes were palpable within scrotum. Patient had subcoronal hypospadias, minor chordee, ventral urethral wall was hypoplastic and thin. All sacral vertebrae were palpable. Rest of spine was normal. Systemic examination was normal. Baby was worked up for various associated congenital anomalies. Ultrasound (USG) abdomen showed non-visualization of right kidney, left kidney was normal. This was confirmed by CT scan. A 2-Dimensional echo study of the heart was normal. Micturating cystourethrogram showed good bladder capacity, smooth mucosa, no vesicoureteral reflux, and no evidence of any fistula. Parents were given detailed information about the possible diagnosis and were counseled regarding staged correction of rectoperineal fistula and associated hypospadias. Since baby was defecating well through anteriorly displaced ectopic anus definitive surgery was planned, by taking the informed consent of the parents, after baby was above 3 kg. Patient was kept on weekly follow-up visits to the outpatient department. On gaining the weight, patient was admitted. His routine blood investigations were done along with fitness for anesthesia. Patient was kept nil by mouth before 12 hours before the operative procedure. Anal wash was given along with enema a day before the surgery and repeated on the morning of the surgery.

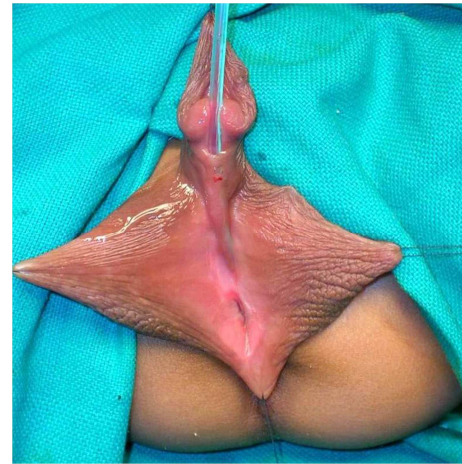


**Figure 1.** Skin lined anus placed within bifid scrotum, sub coronal hypospadias, thin ventral urethral wall, thin perineal body.

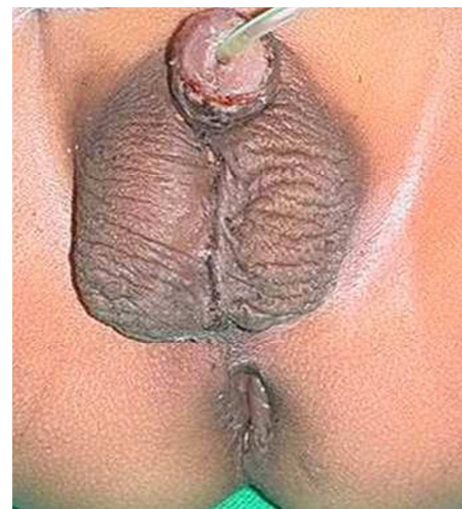*Operative procedure:*

The patient was kept in lithotomy position under general anesthesia. Subcoronal meatus was identified and catheterized with No 7 infant feeding tube connected to the urine collecting bag. Proposed anal site was identified with the help of muscle stimulator. It was checked and was marked accordingly. Ventral urethral wall was formed by flimsy thin membrane extending till the anterior wall of ectopic anus. Inverted V shaped incisions were marked. Incisions were taken at proposed anal site. Skin flap was raised. An anal dilator was

passed into the anus and the rectal pouch was identified with the help of it. Rectal pouch was dissected laterally and posteriorly to create space. Dissection between ventral urethral wall and rectal pouch was done last. While doing this urethral injury occurred at this step because of flimsy and very thin urethral surface and densely adherent scrotal wall. Urethral injury was freshened into urethrostomy with multiple mucocutaneous sutures. Perineal body between urethra and rectal pouch was identified and reconstructed. With reconstruction of perineal body the distance between urethra and neoanus increased to near normal. Adequate mobilization of the pouch was done and anoplasty was completed in two layers with absorbable sutures. Patient was kept nil by mouth for 5 days to avoid any contamination of the wound. The patient was discharged home on the 7th post-operative day after starting on oral liquid diet initially and then shifting to soft diet. Patient passed motion through the created neoanus on day 6<sup>th</sup>. Anal dilatation started after 2 weeks as an outpatient procedure. Repair of hypospadias with urethroplasty was done electively after 6 weeks (Fig. 2, 3).



**Figure 2.** Ureterostomy and neoanus created.



**Figure 3.** Posturethroplasty and hypospadias repair photo.

The patient got good bowel and bladder voiding functions on follow up after 3 months.

### 3. Discussion

Anorectal malformations (ARM) represent a spectrum of abnormalities ranging from mild anal anomalies to complex cloacal malformations. The etiology of such malformations remains unclear and is likely multifactorial. Important associated anomalies include genitourinary defects, which occur in approximately 50% of all patients with anorectal malformations. All patients must be evaluated at birth to rule out one of these defects, and the most valuable screening test is an abdominal and pelvic ultrasound.

Unlike other anorectal malformations and Hirschsprung's disease which have higher incidence rate in males. Among boys with low ARM, the minor abnormalities at the external anal orifice are associated with deeper anatomical aberrations in the form of anterior misplacement of the anorectum. [16] Anteriorly displaced anus occurs more often in females than in males with a ratio of approximately 2:1. Moreover, the presence of co-existing abnormalities has not been observed in ADA patients, as in anorectal malformations and Hirschsprung disease [12, 13] Newborns with anorectal malformations are commonly diagnosed immediately after birth either because of absence of a normally located anus or when they pass small amounts of meconium through an abnormally placed opening. Newborns with anterior ectopic anus on the other hand usually have a normal looking anal opening and so escape identification during the newborn period and many of these patients present subsequently with constipation [1, 2] Anterior ectopic anus is a normal looking anus but anteriorly displaced and the external anal sphincter is distributed all around the circumference of the anal canal, including the ventral aspect of the anal canal as was evaluated by preoperative magnetic resonance imaging [3].

We are unable to explain the embryology of this condition. Kluth, [15] in his animal model studies, noticed that the normal embryology of the hindgut clearly demonstrates that the area of the future anal orifice is formed in an early phase of development, and forms a fixed point in cloacal and hindgut development. He also noted that in all abnormal mouse embryos, the dorsal cloacal membrane and the dorsal cloaca were missing. These structures are considered essential for the normal establishment of the anal orifice and the lower rectum. In case of a defective cloacal anlage, a missing or misplaced anal orifice may result [15]. Anterior ectopic anus is characterized by a short perineal body and it is believed to result from developmental malformation of the mid-portion of the external anal sphincter which leads to weakness of corresponding segment of the anal canal [4]. The normal anal position is midway between the vaginal fourchette and coccyx in females and the scrotum and coccyx in males. The anal position index is a simple method used to evaluate the anal position. Initially this was first described by Bar-Maor and Eitan and called it the anogenital index which was modified subsequently by Reisner *et al.* who called it the anal position index [5, 7]. The anal position index was defined as the ratio of the scrotal-anal distance to the scrotal-coccygeal distance in boys, and as the ratio of the fourchette-anal distance to the

fourchette-coccygeal distance in girls [5, 7]. An anal position index of less than 0.34 in girls and less than 0.46 in boys is diagnostic of an anterior ectopic anus. Anterior ectopic anus is believed to be more common than was previously thought and it is much more common in girls than boys. In a previous study on 357 children (191 boys and 166 girls), the incidence of anterior ectopic anus was 43.4% in girls and 24.6% in boys ( $P < 0.01$ ) [1]. Preoperative Magnetic resonance imaging (MRI) documentation of sphincter distribution is recommended for the diagnosis of AEA, as it would help in better definition of its association with constipation and the results of surgical management [14, 17].

There are several surgical techniques to treat anterior ectopic anus. These include cutback, posterior anal transposition, posterior sagittal ano-rectoplasty (PSARP), posterior anoplasty with sphincterotomy and anterior sagittal ano-rectoplasty (ASARP) [8, 9]. Some of these procedures are extensive, may not be cosmetically acceptable and may necessitate a preliminary diverting colostomy. Anal shift procedure on the other hand is a simple and safe surgical procedure with good functional and cosmetic results [10]. It does not necessitate a preliminary diverting colostomy and the minimal dissection eliminates the chances of stricture and anal stenosis associate with cut back anoplasty, ASARP and constipation associated with PSARP.

### 4. Conclusion

Surgical correction is important in patients of anterior ectopic anus to treat constipation and have a good cosmetic appearance. Although, there are several surgical techniques to treat anterior ectopic anus, Anal Shift operation is a simple and safe procedure with good functional and cosmetic results.

---

### References

- [1] Herek O, Polat A. Incidence of anterior displacement of the anus and its relationship to constipation in children. *Surg Today* 2004; 34 (2): 190-2.
- [2] Leape LL, Ramenofsky ML. Anterior ectopic anus: A common cause of constipation in children. *J Pediatr Surg* 1978; 13 (6D): 627- 630.
- [3] Thambidorai CR, Raghu R, Zulfiqar A. Magnetic resonance imaging in anterior ectopic anus. *Pediatr Surg Int* 2008; 24 (2): 161-5.
- [4] Upadhyaya P. Mid-anal sphincteric malformation, cause of constipation in anterior perineal anus. *J Pediatr Surg* 1984; 19: 183- 186.
- [5] Reisner SH, Nitzan M. Determination of anterior displacement of the anus in the newborn infants and children. *Pediatrics* 1984; 73: 216-217.
- [6] Erturk N, Kandemir O. Determination of normal anal position index using a modified technique in Turkish neonates. *Journal of Indian Association of Pediatric Surgeons*. 2017 Jan 1; 22 (1): 29.

- [7] Bar-Maor JA, Eitan A. Determination of the normal position of the anus (with reference to the idiopathic constipation). *J Pediatr Gastro-Enterol Nutr* 1987; 6: 559-561.
- [8] Tuggle DW1, Perkins TA, Tunell WP, Smith EI. Operative treatment of anterior ectopic anus: the efficacy and influence of age on results. *J Pediatr Surg*. 1990; 25 (9): 996-7.
- [9] Abeyaratne M. Posterior transposition of anterior ectopic anus. *J Pediatr Surg* 1991; 26 (6): 725-.
- [10] Shah AJ, Bhattacharjee N, Patel DN, Ganatra JR. Anal shift: preliminary results. *J Pediatr Surg* 2003; 38 (2): 196-8.
- [11] Rerksuppaphol S, Rerksuppaphol L. Anterior displacement of anus: a common association with constipation in infancy. *Asian Biomed*. 2011 Mar 16;4 (4): 595.
- [12] Levitt MA, Pena A. Anorectal malformations. *Orphanet J Rare Dis*. 2007; 2: 33.
- [13] Godbole K: Many faces of hirschsprung's disease. *Indian Pediatr*. 2004; 41: 1115-23.
- [14] Thambidorai CR, Raghu R, Zulfiqar A. Magnetic resonance imaging in anterior ectopic anus. *Pediatric surgery international*. 2008 Feb 1; 24 (2): 161-5.
- [15] Kluth D. Embryology of anorectal malformations. In *Seminars in pediatric surgery* 2010 Aug 31 (Vol. 19, No. 3, pp. 201-208). WB Saunders.
- [16] AbouZeid AA, Mohammad SA. Low-type anorectal malformations in the male: extent of deviation from the norm. *Journal of Pediatric Surgery*. 2016 Jun 6.
- [17] Ziegelmann MJ, Viers BR, Cockerill PA, Viers LD, Matsumoto JM, Granberg CF. The Utility of Magnetic Resonance Imaging in the Evaluation of Accessory Scrotum in the Newborn. *Urology*. 2016 Jun 16.